

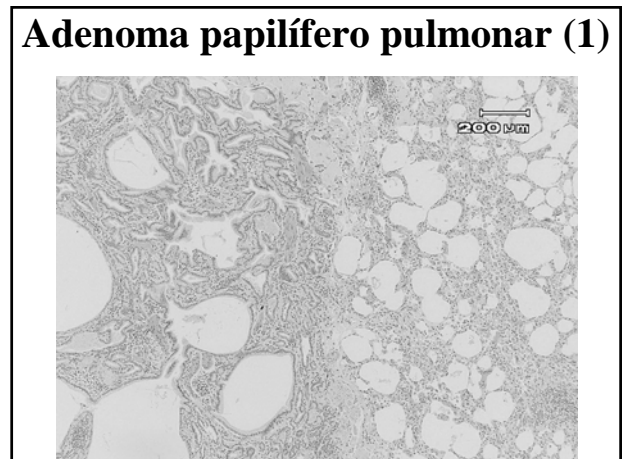
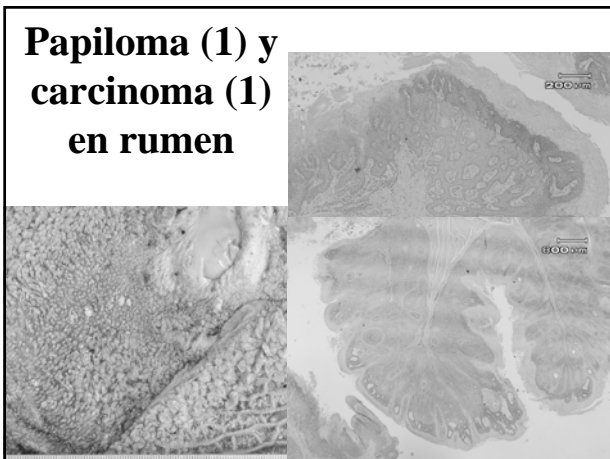
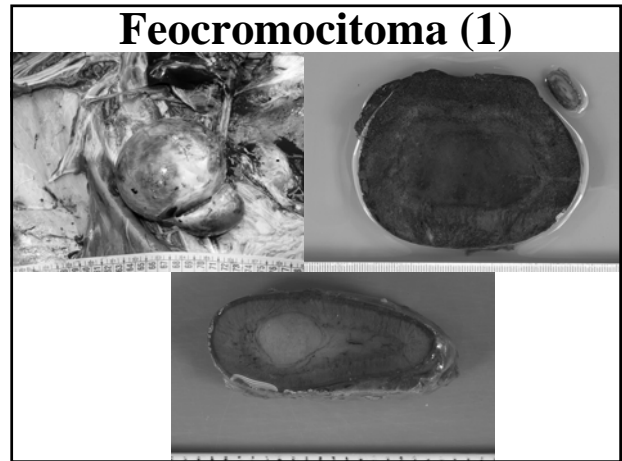
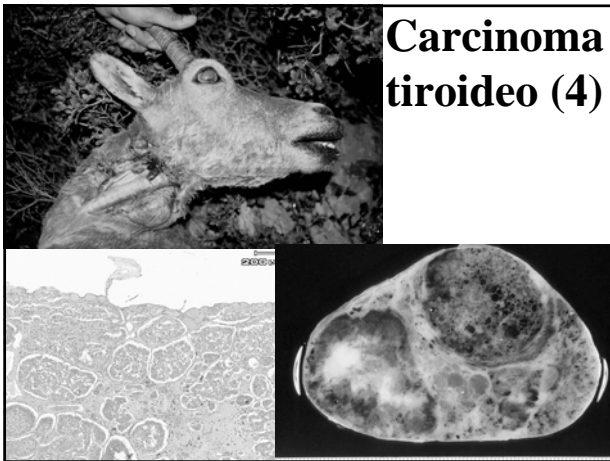
## Neoplasias en Ruminantes Silvestres

Arnal, M.C.; Fernández de Luco, D.; Ferroglio, E.; Formisano, C.; Cortázar, C.; Höfle, U.; Martín, M.P.; Meneguz, P.G.; Revilla, M.; Rossi, L.; Vicente, J.



## Cabra montesa *Capra pyrenaica*

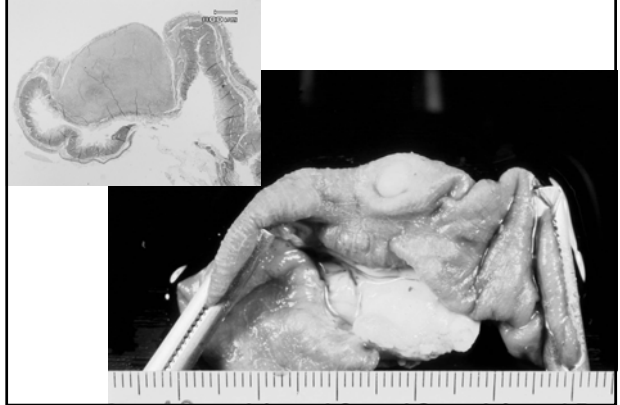
- Carcinoma tiroideo (4)
- Feocromocitoma (1)
- Carcinoma de células escamosas en rumen (1)
- Papiloma en rumen (1)
- Adenoma papilífero en pulmón (1)
- Cuerno cutáneo (1)
- Leiomioma intestinal (1)




### Cuerno cutáneo (1)



### Leiomioma intestinal (1)



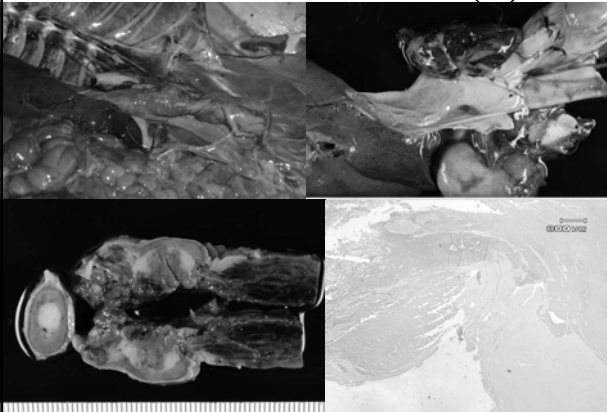
### Muflón *Ovis aries musimon* - Carcinoma de células escamosas en rumen (1)



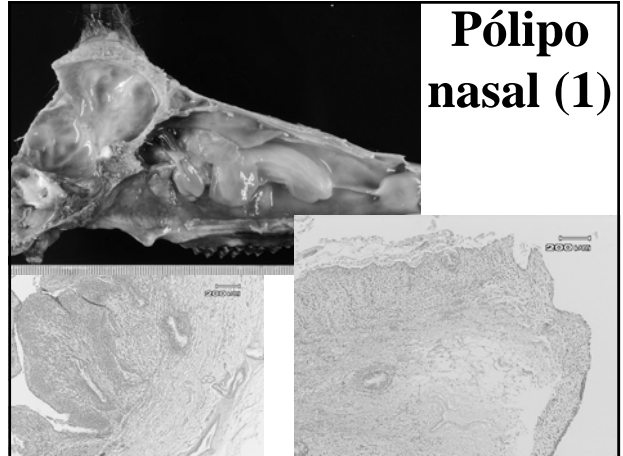
### Sarrio *Rupicapra p. pyrenaica*

- Feocromocitoma (1)
- Pólipo nasal (1)

### Feocromocitoma (1)



### Pólipo nasal (1)

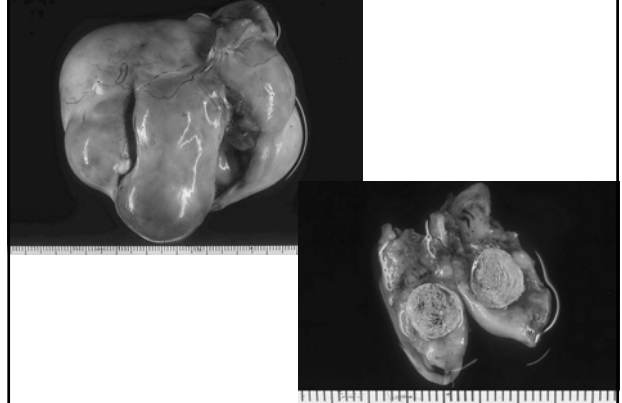


## Ciervo

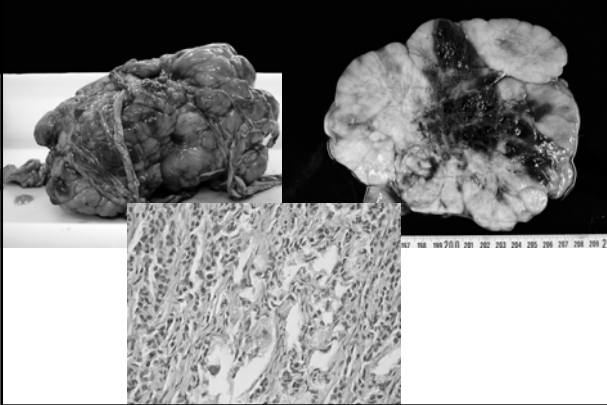
### *Cervus elaphus*

- Teratoma bilateral de ovario (1)
- Mesotelioma (1)
- Fibropapiloma cutáneo (1)


## Teratoma ovárico (1)



## Mesotelioma (1)



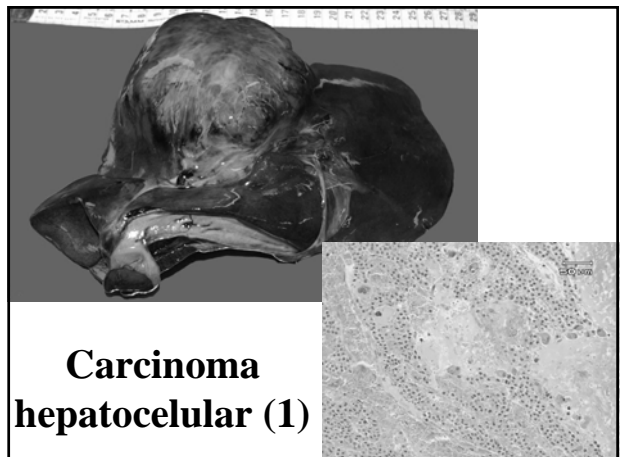
## Fibropapiloma cutáneo (1)



## Corzo

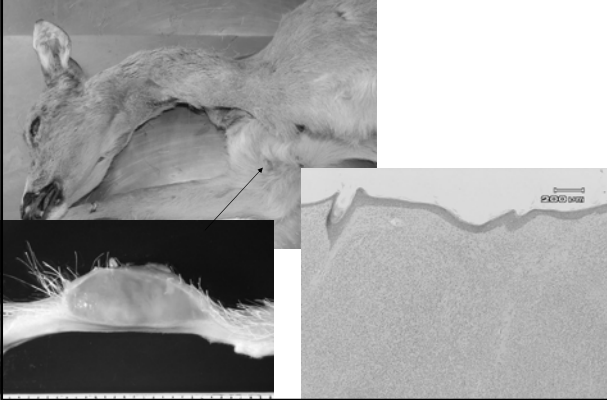
### *Capreolus capreolus*

- Carcinoma hepatocelular (1)
- Linfoma cutáneo (1)
- Fibropapiloma gingival (1)
- Papiloma esofágico (1)
- Papiloma en librillo (1)

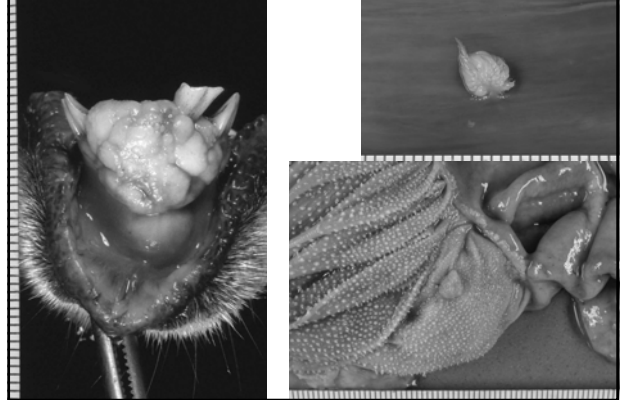


## Carcinoma hepatocelular (1)

## Linfoma cutáneo (1)



## Papilomas digestivos (3)



**MUCHAS GRACIAS**

