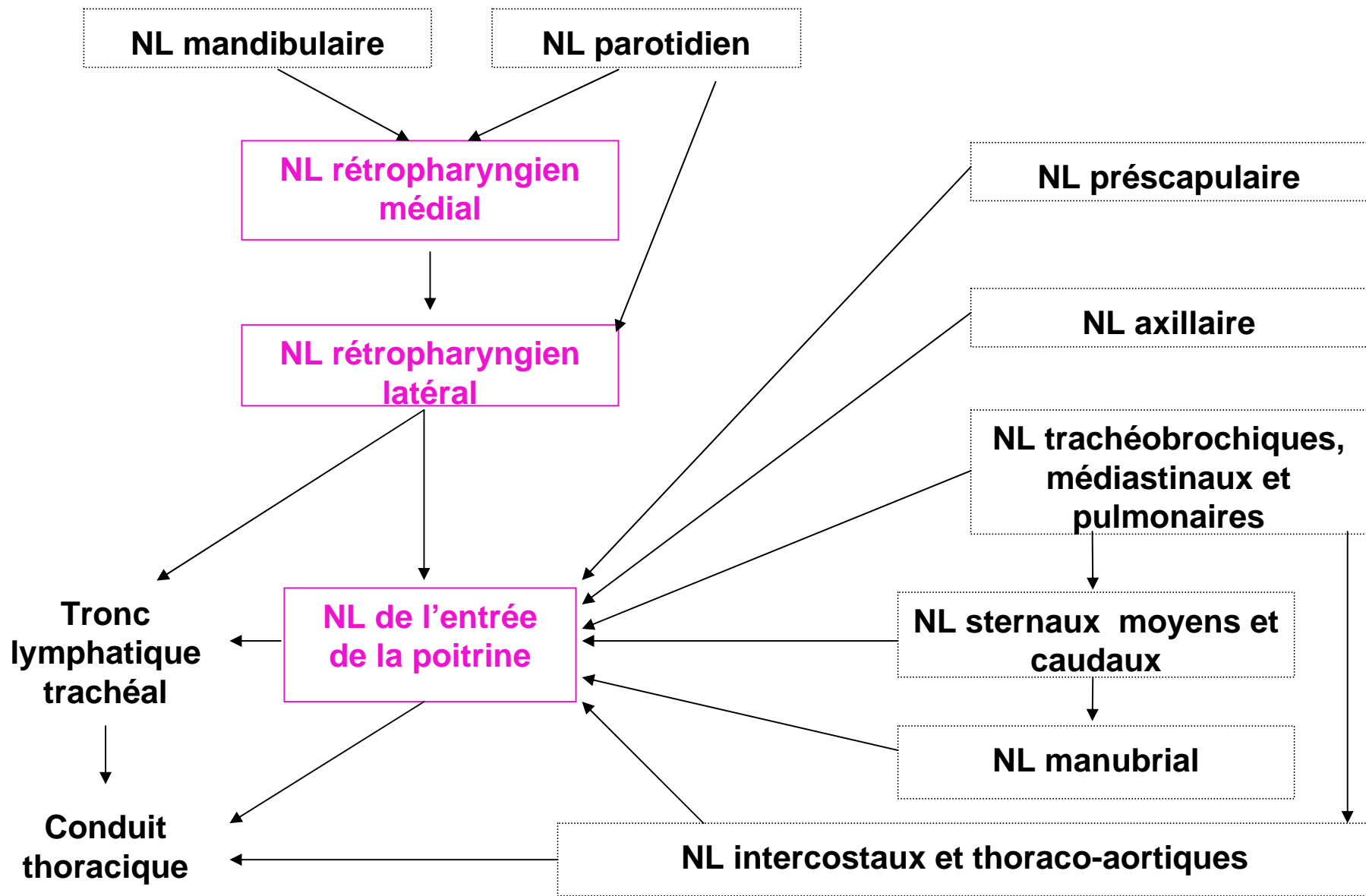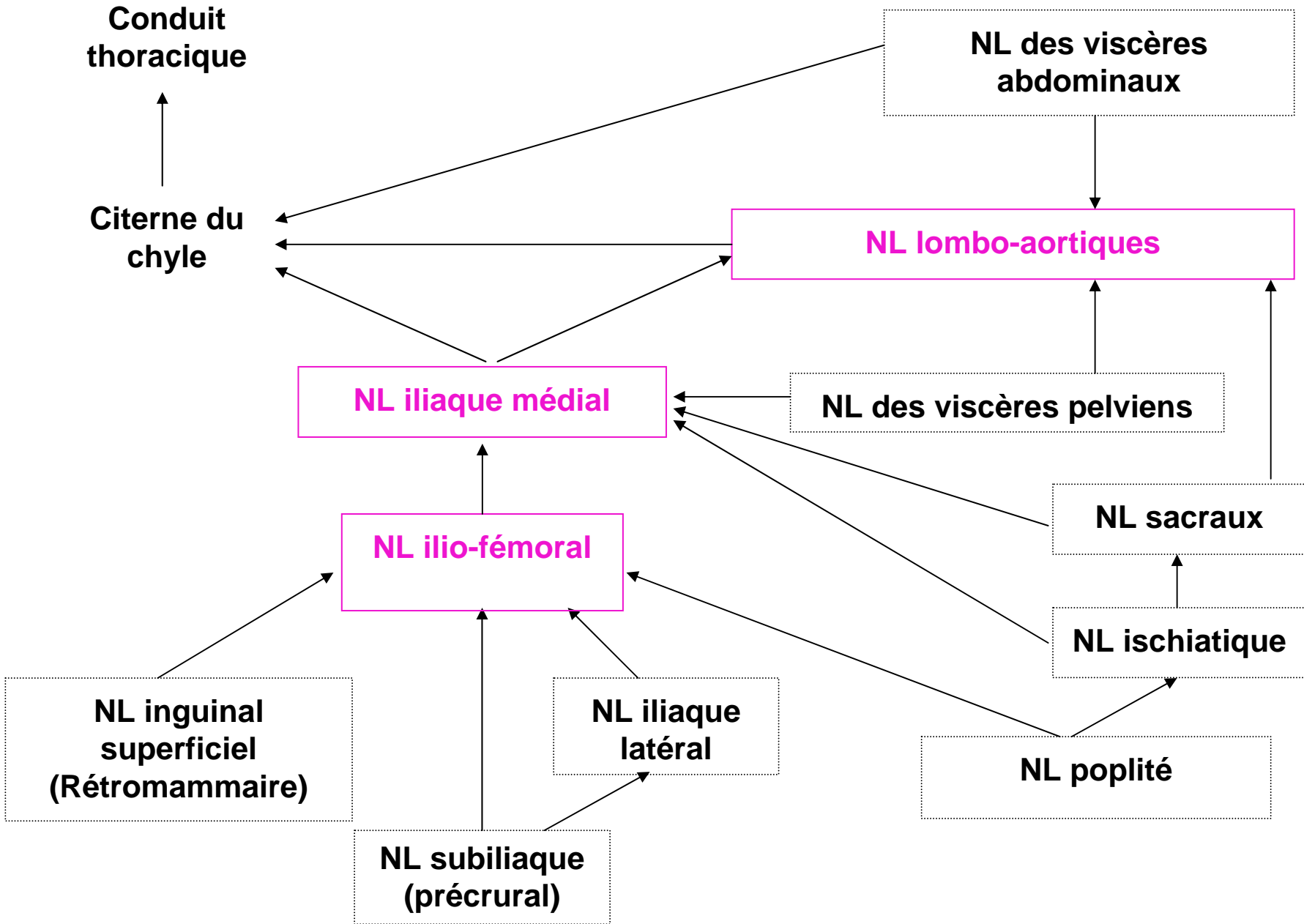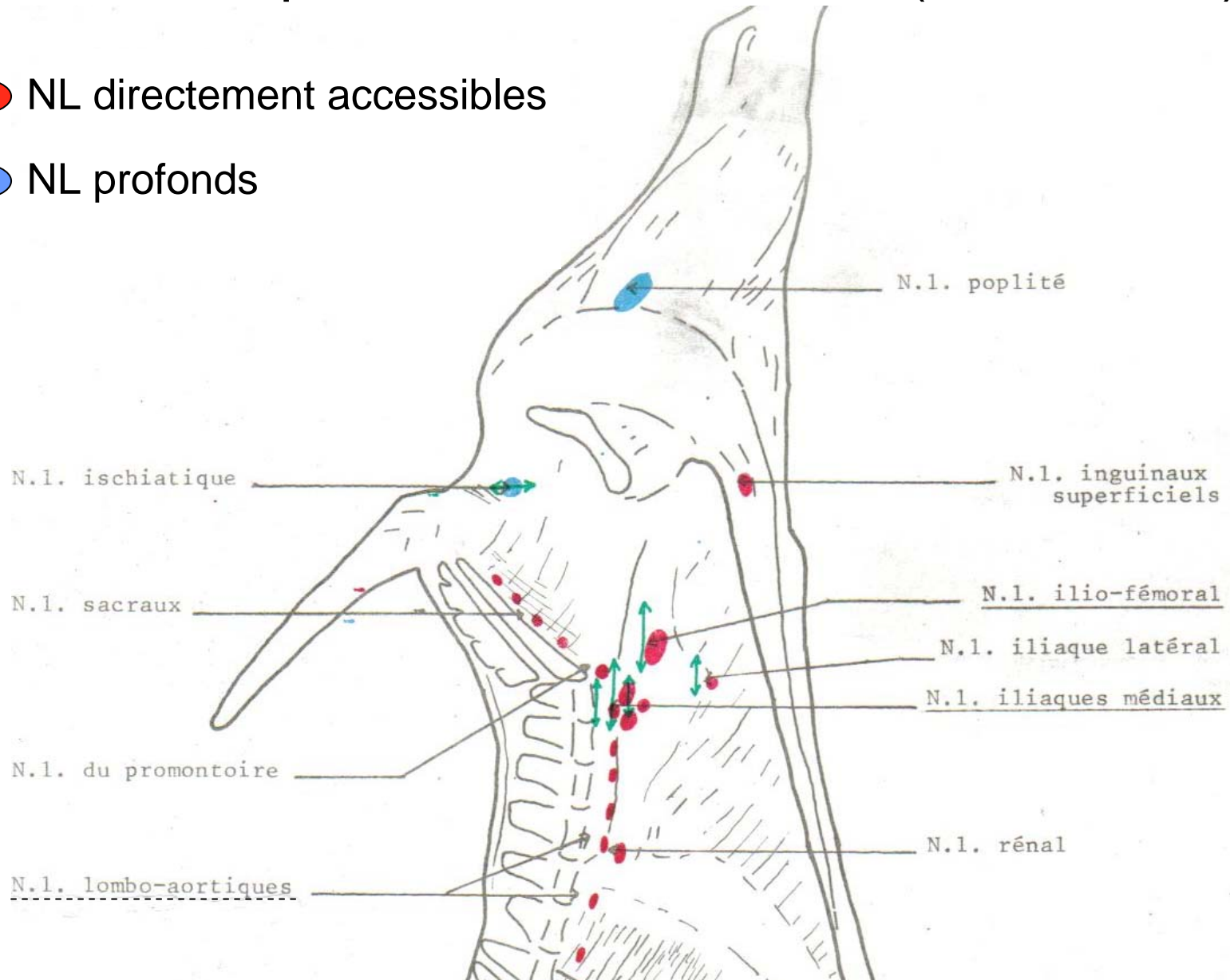


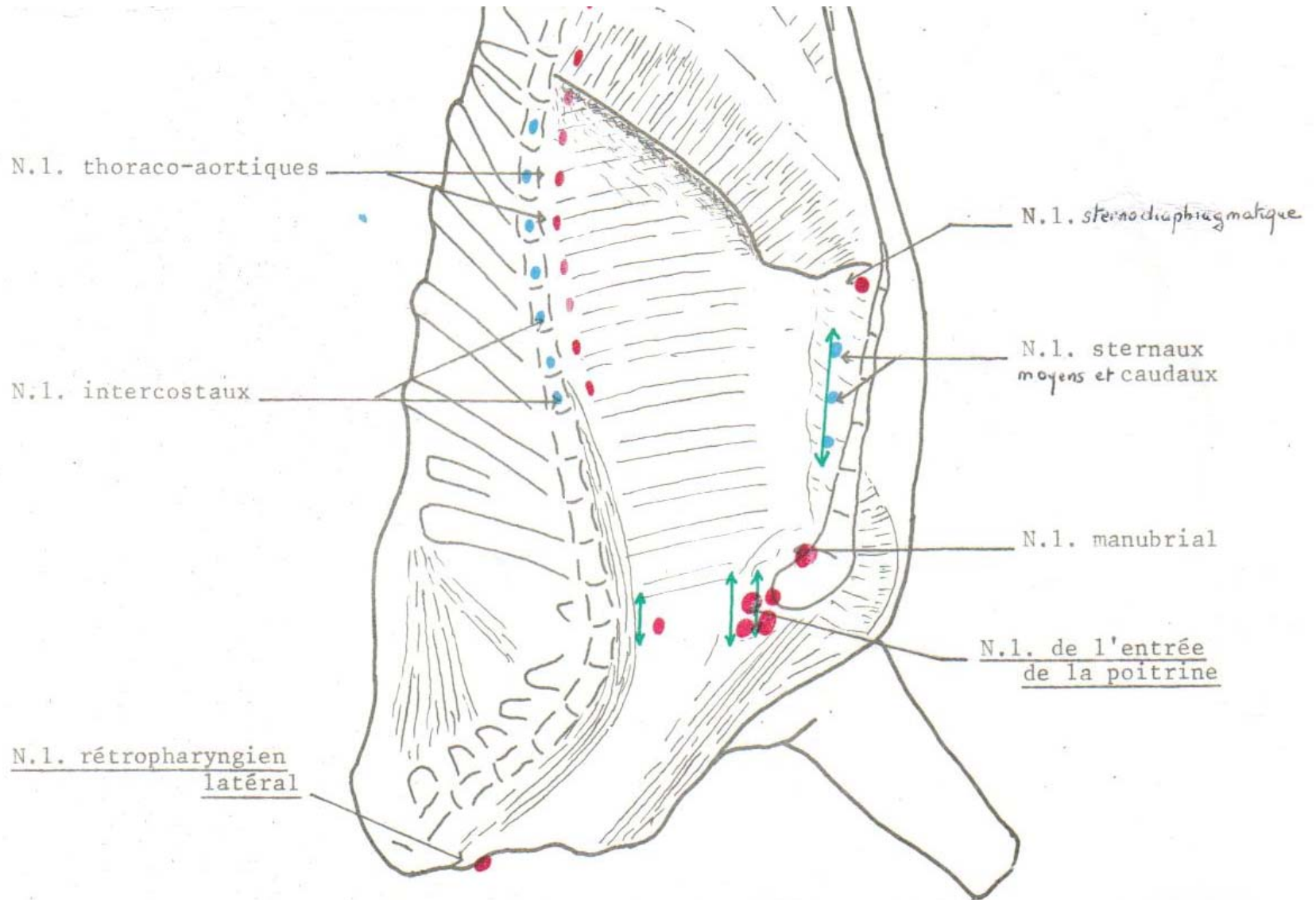
NL du quartier arrière du bœuf (vue interne)

● NL directement accessibles

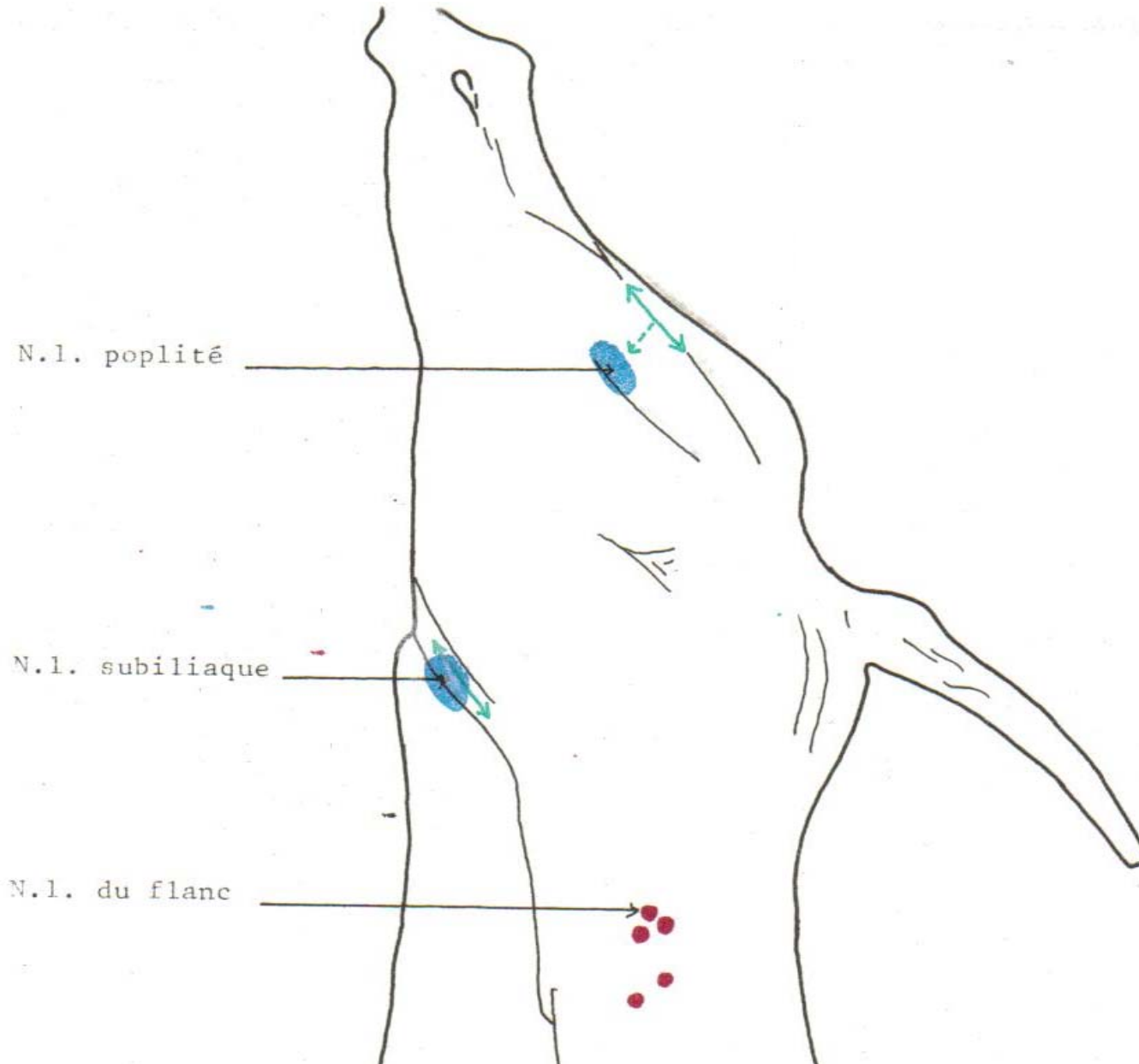
● NL profonds



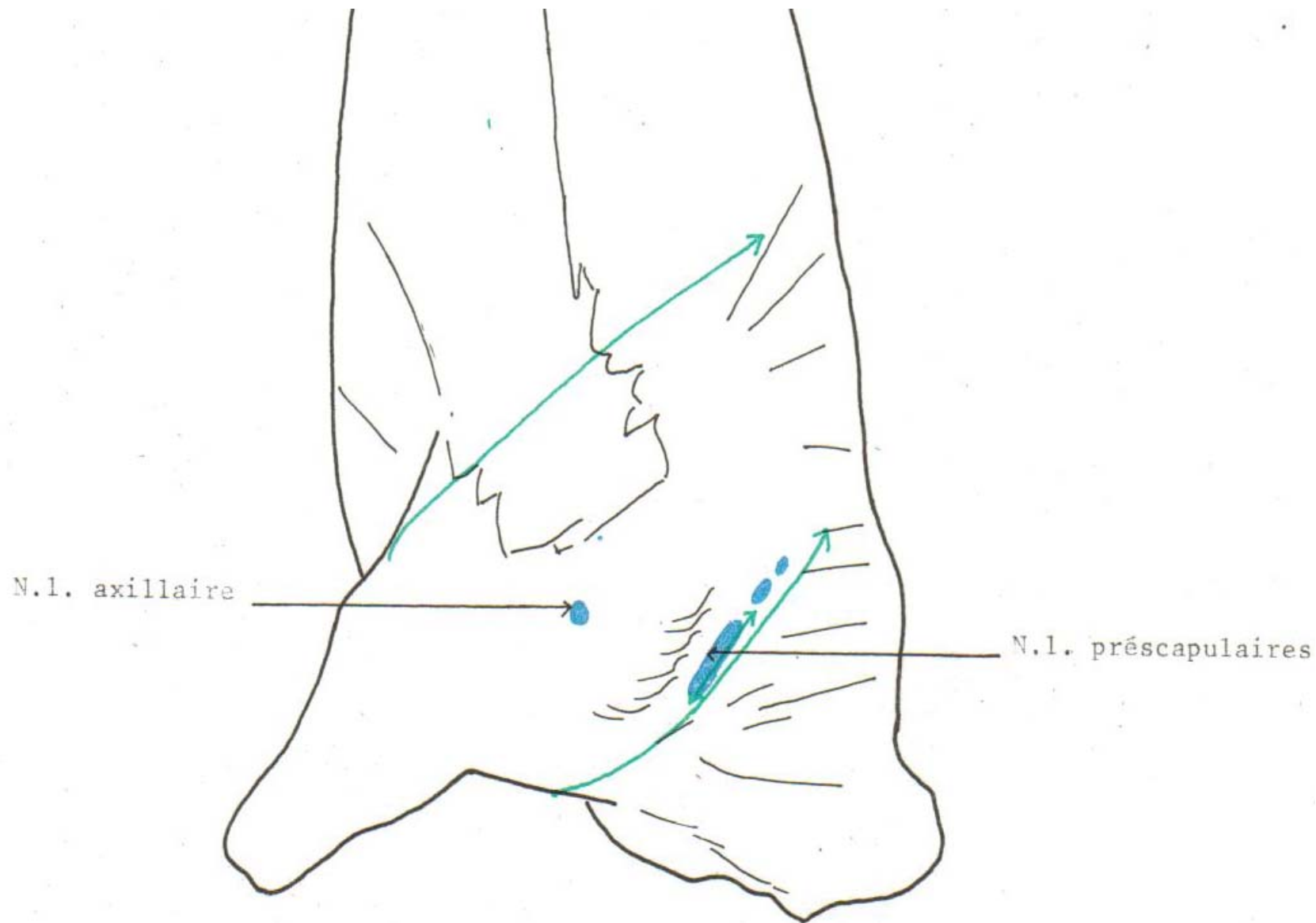
NL du quartier avant du bœuf (vue interne)



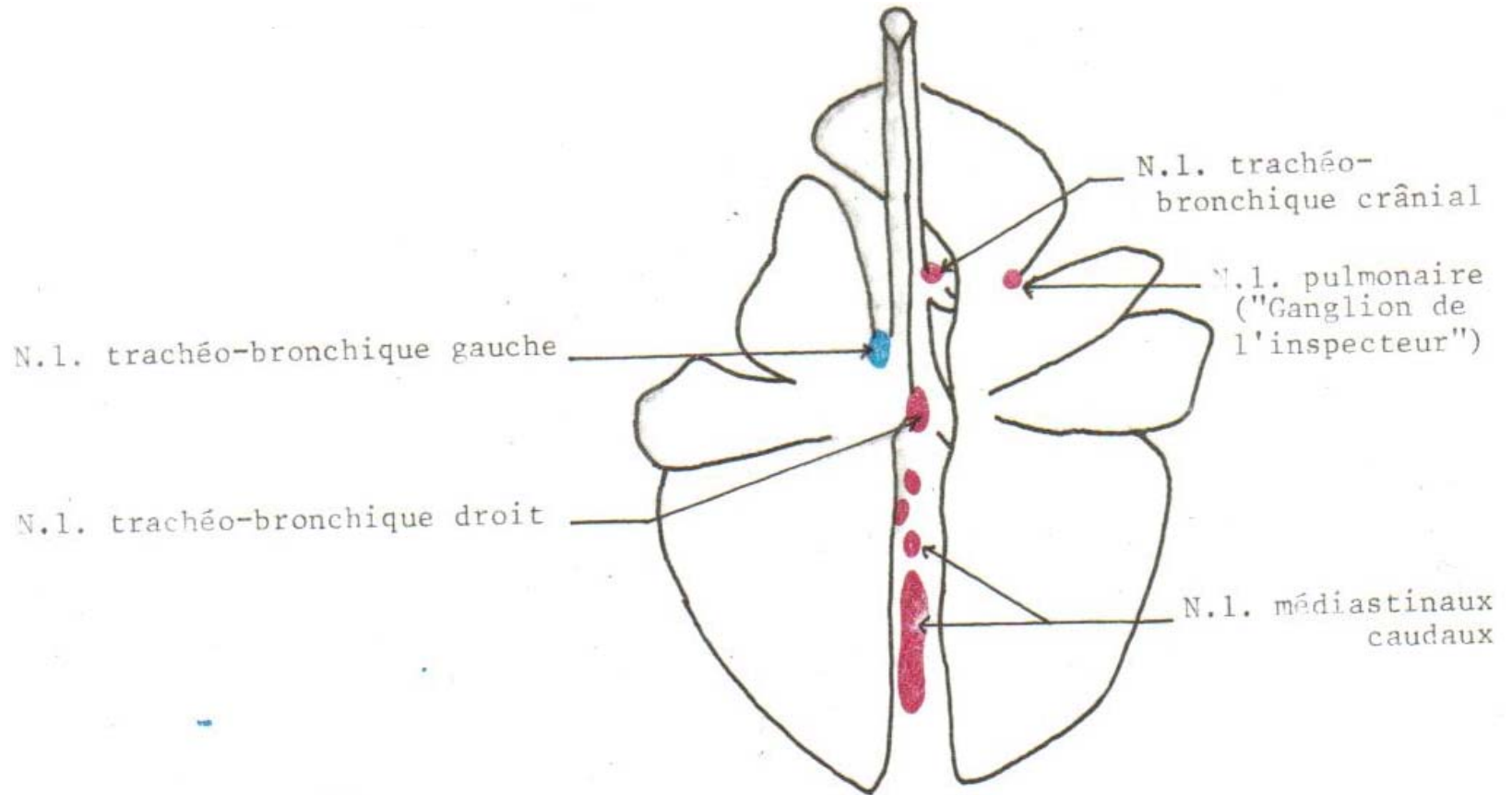
NL du quartier arrière du bœuf (vue externe)



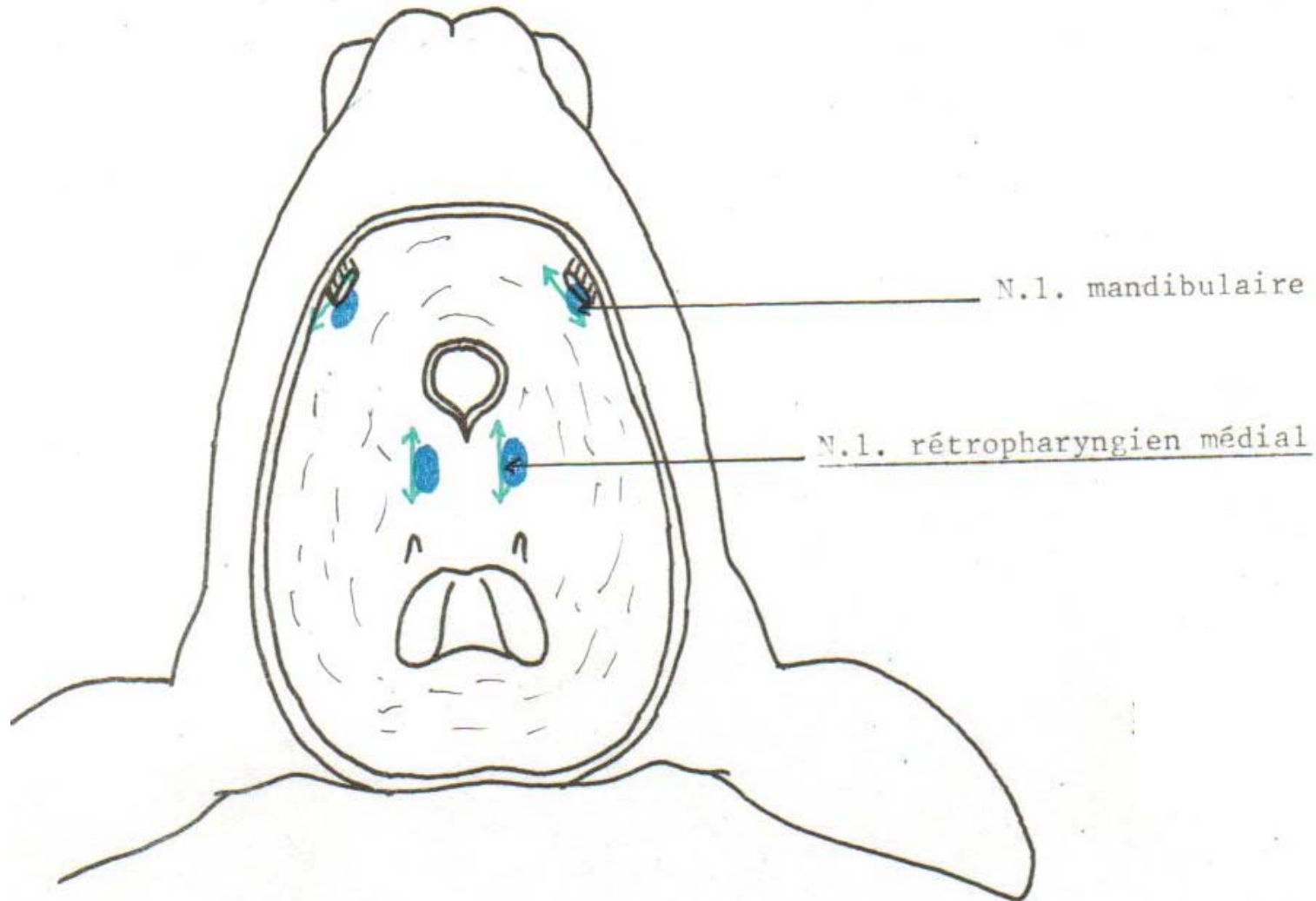
NL du quartier avant du bœuf (vue externe)



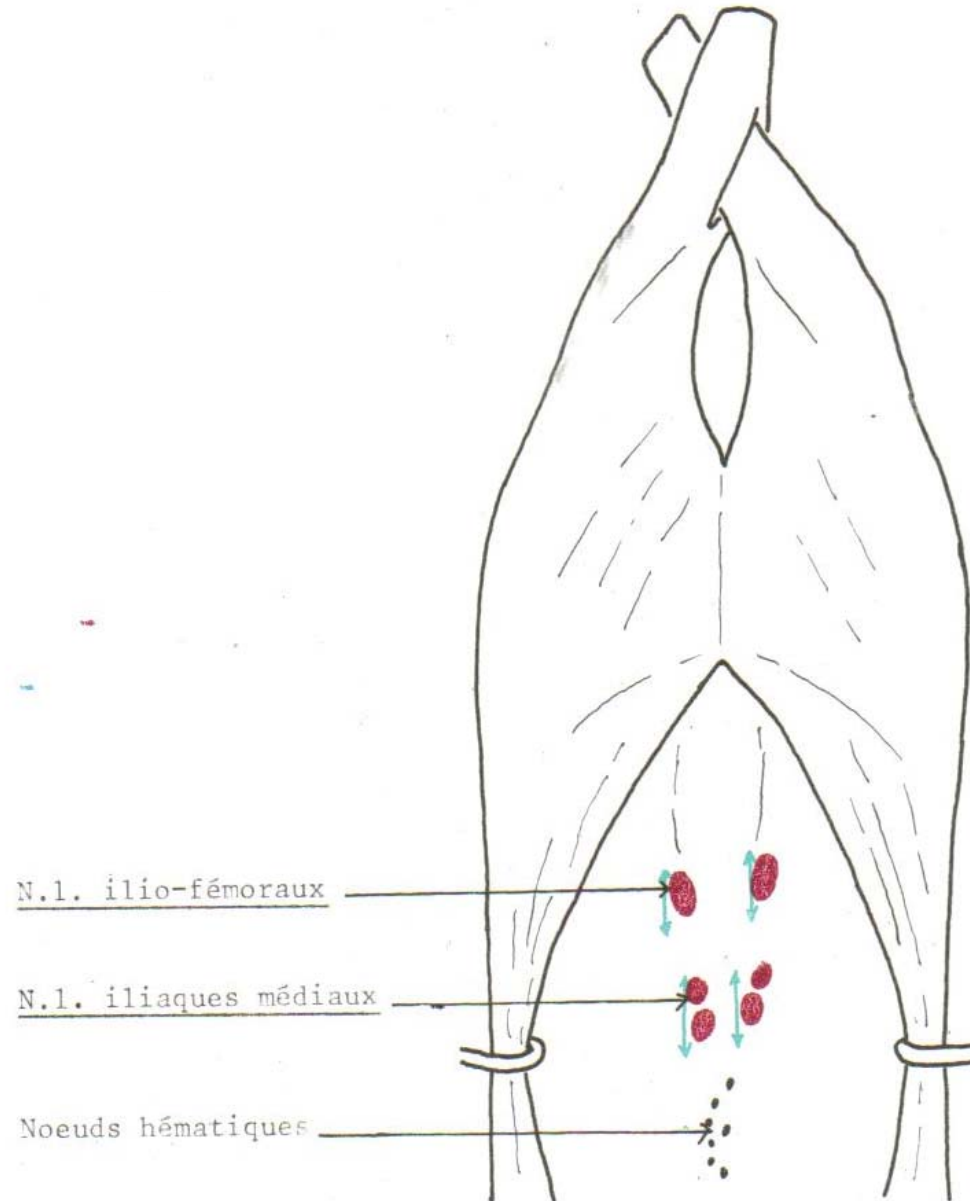
NL du poumon chez le boeuf



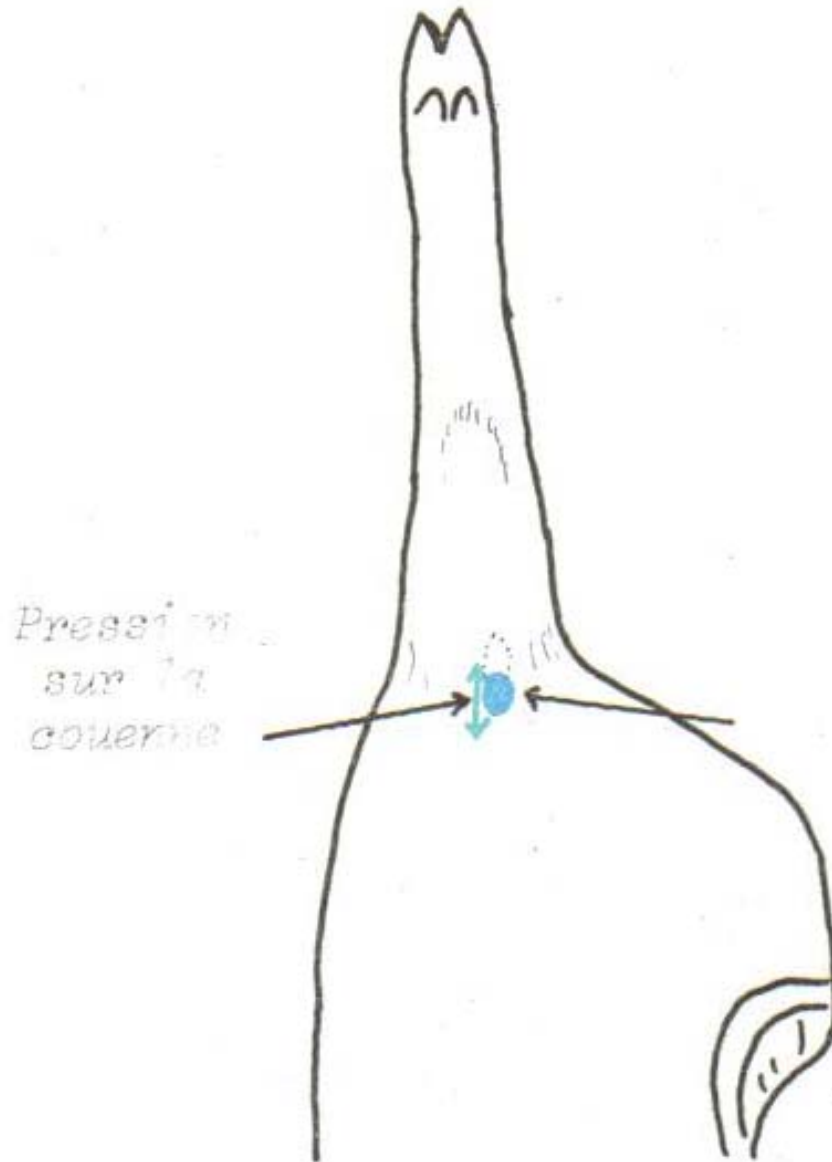
NL de la tête du veau (vue postérieure)



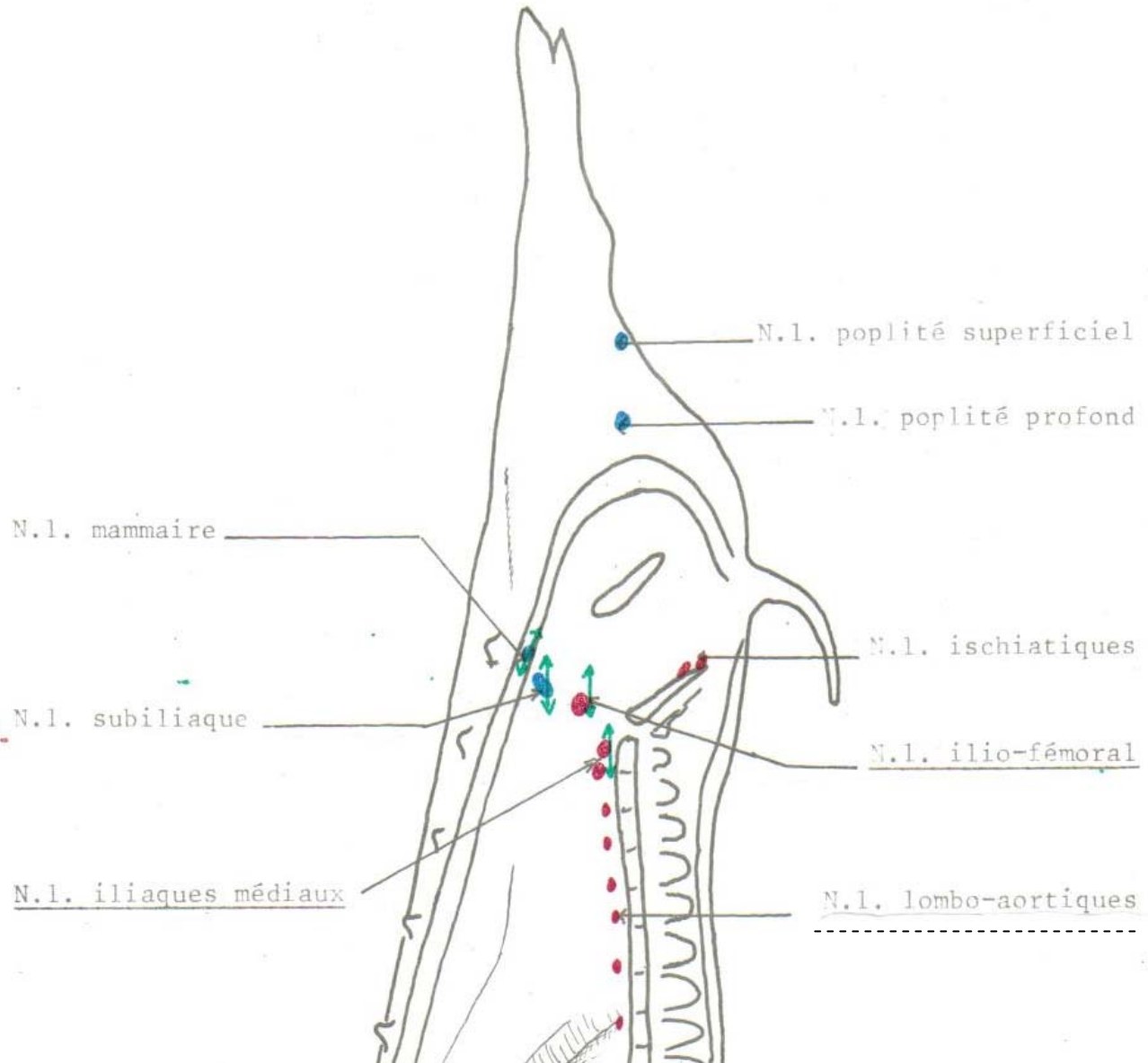
NL de la cavité abdominale des ovins



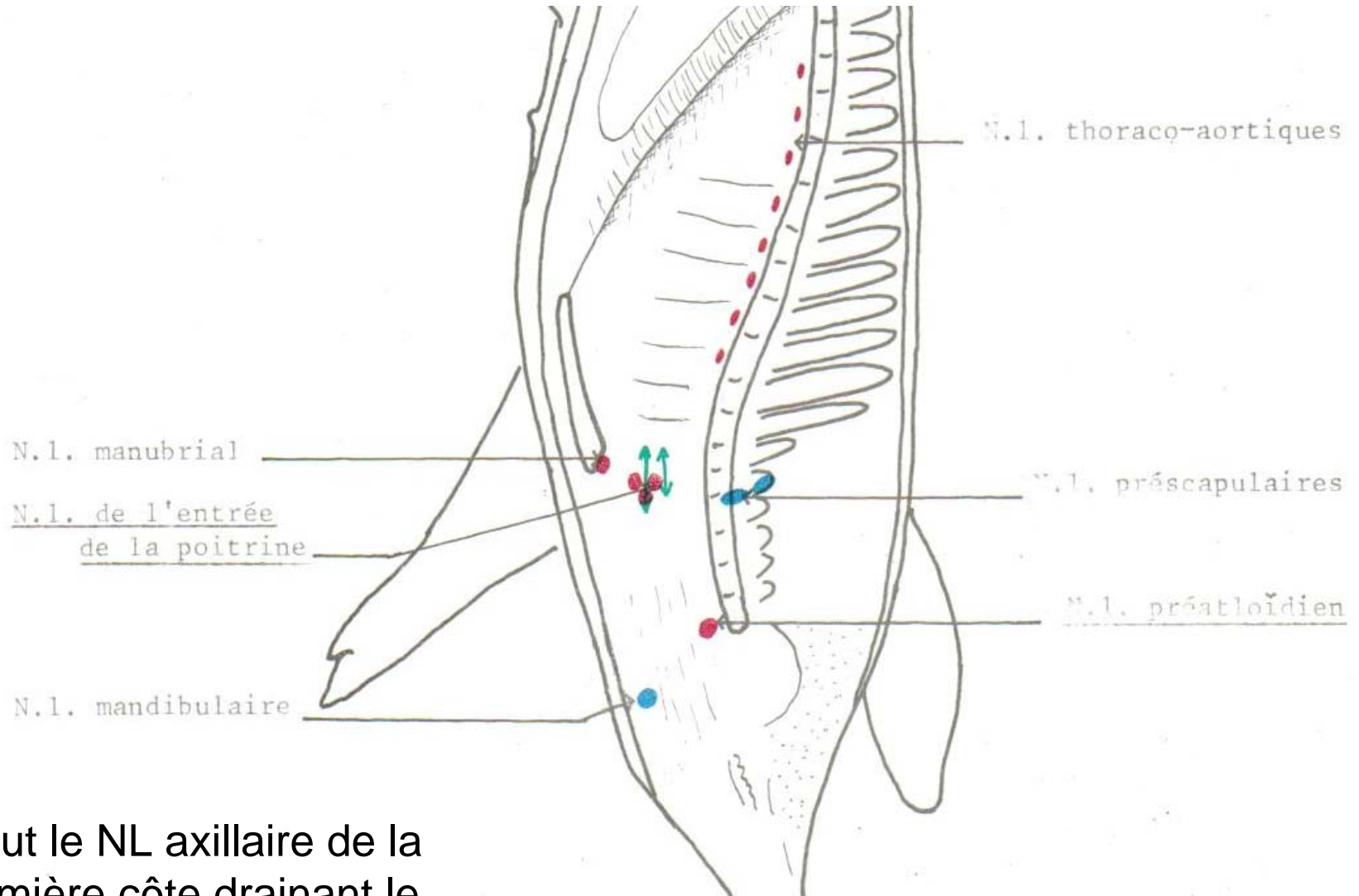
NL poplité superficiel du porc



NL du quartier arrière du porc (vue interne)



NL du quartier avant du porc (vue interne)



Inclut le NL axillaire de la première côte drainant le membre antérieur